Same Setting Laparoscopic Antegrade Continence Enema and Antegrade Bladder Neck Injection for Constipation and Urinary Incontinence in the Spina Bifida Population

Jonathan D. Kaye, S. Mohammad A. Jafri, Scott P. Cuda, Jonathan F. Kalisvaart, Wolfgang H. Cerwinka and Andrew J. Kirsch*,†

From the Department of Pediatric Urology, Children's Healthcare of Atlanta-Emory University School of Medicine, Atlanta, Georgia

Abbreviations and Acronyms

ABNI = antegrade bladder neck injection

ACE = antegrade continence enema

Dx/HA = dextranomer/hyaluronic acid

LACE = laparoscopic ACE

RLQ = right lower quadrant

UDS = urodynamics

VLPP = Valsalva leak point pressure

Study received institutional review board approval.

* Correspondence: (e-mail: akirschmd@aol.com).

† Financial interest and/or other relationship with Q-Med and Cook.

Purpose: Fecal impaction and urinary incontinence and are among the most important problems in patients with spina bifida. We report our preliminary results with a minimally invasive approach to these 2 problems, that is same setting laparoscopic antegrade continence enema and antegrade bladder neck injection.

Materials and Methods: We reviewed the charts of all patients who underwent same setting laparoscopic antegrade continence enema and antegrade bladder neck injection between January 1, 2006 and August 1, 2008. Demographic data, surgical indications, operative details and results were recorded. Surgical steps were uniform in all cases. Diagnostic laparoscopy was performed. Two additional 5 mm trocars were placed. The appendix was mobilized to reach skin in the right lower quadrant. The antegrade continence enema channel was matured. A small percutaneous cystotomy was then created via the suprapubic port site. The cystoscope was passed suprapubically and dextranomer/hyaluronic acid was injected in the bladder neck. A suprapubic tube was placed.

Results: We performed a total of 10 same setting laparoscopic antegrade continence enemas with antegrade bladder neck injection in 4 males and 6 females with a mean age of 9.4 years (range 6 to 13). All patients had a smooth walled bladder on cystogram, and good capacity, good compliance and low leak point pressure on urodynamics. There were no intraoperative complications and all patients were discharged home within 24 hours. At an average 18-month followup (range 12 to 27) all 10 patients were continent of stool and reported marked improvement in daily care. No patient experienced stool or gas leakage via antegrade bladder neck injection. Seven of 10 patients (70%) were continent of urine and no longer wore diapers.

Conclusions: Same setting laparoscopic antegrade continence enema with antegrade bladder neck injection is a safe, efficacious, reasonably simple minimally invasive approach to severe constipation and urinary incontinence in patients with spina bifida.

Key Words: urinary bladder, laparoscopy, enema, dextranomer-hyaluronic acid copolymer, spinal dysraphism

FECAL impaction and urinary incontinence are among the most important problems in patients with spina bifida. A wide spectrum of treatment options exists in these patients, ranging from pharmacological therapy to open reconstructive surgery.

ACE has significantly impacted the lives of patients with spina bifida, in whom constipation is refractory to di-

0022-5347/10/1844-1644/0
THE JOURNAL OF UROLOGY®

Vol. 184, 1644-1650, October 2010
Printed in U.S.A.
DOI:10.1016/j.juro.2010.04.018

etary and pharmacological intervention as well as to retrograde enemas. As first described in 1990 by Malone et al,[1] this technique uses the appendix as a catheterizable channel through which irrigant is instilled into the right colon. Antegrade irrigation then flushes the entire large intestine of its contents, ameliorating constipation and providing significant fecal continence.

Bladder neck bulking is a common treatment modality in patients with low leak point pressure due to poor outlet resistance. Cystoscopic injection via antegrade, retrograde and combined approaches have been described with various degrees of success.[2] Injection can be done as a single procedure in patients with a compliant bladder of normal or almost normal capacity. It can also be combined with augmentation cystoplasty or intravesical botulinum toxin injection in patients with a poorly compliant bladder and/or a bladder with pathologically small volume.

We report our preliminary experience with a minimally invasive approach to these 2 problems, that is same setting LACE and ABNI. We compared our results using the combined approach to those in prior reports of each procedure done individually. We determined the feasibility, safety and efficacy of combined, minimally invasive approaches to fecal impaction and urinary incontinence in the spina bifida population. To our knowledge this is the first such report in the literature.

MATERIALS AND METHODS

We obtained institutional review board approval for this retrospective chart review. We reviewed the charts of all patients with myelomeningocele who underwent same setting LACE and ABNI between January 1, 2006 and August 1, 2008. Demographic data, surgical indications, ambulatory status, preoperative and postoperative diaper status, operative details and outcomes were recorded.

Surgical Eligibility

Eligibility for surgery included bladder capacity greater than 80% of that expected for age, normal bladder compliance, manual dexterity to perform catheterization and absent prior bladder neck surgery, appendectomy or Mitrofanoff procedure. All children underwent preoperative videoUDS to ensure adequate bladder compliance and capacity, and document preoperative VLPP. When an irregular or trabeculated bladder was found on cystogram and a pathologically low capacity or poorly compliant bladder was noted on UDS (less than 20 ml/cm H_2O), the patient was not offered this procedure. Prior ventriculoperitoneal shunting for hydrocephalus did not preclude this procedure. Parents were informed that this procedure represents an off label use of Dx/HA.

Success Definitions

LACE was considered successful when the patient met 4 criteria postoperatively, including 1) freedom from manual disimpaction, 2) continued daily use, 3) no stool or gas leakage via the stoma and 4) reported satisfaction with the procedure. For ABNI parents were asked about preoperative diaper use and whether postoperative diaper use was about the same, improved or nonexistent at the most recent followup of at least 12 months. For satisfaction patients/parents were asked whether quality of life had worsened, not changed or improved since surgery. Postoperatively all patients underwent annual renal/bladder ultrasound with UDS when there were upper tract changes or they remained incontinent of urine.

Surgical Technique

Laparoscopic ACE. All patients received home bowel preparation using oral antibiotic and retrograde enemas preoperatively. After placing a urethral catheter pneumoperitoneum was achieved with a Veress needle. Diagnostic laparoscopy was done through a 5 mm infraumbilical incision with a 0-degree laparoscope to ensure appendiceal presence and usability. The potential right upper quadrant location of the cecum and appendix in the spina bifida population make this step especially important. After appendiceal adequacy was confirmed 2 additional 5 mm Step® bladeless trocars were placed, including 1 at McBurney's point and another 2 finger breadths superior to the symphysis pubis. Skin incision for the RLQ trocar at McBurney's point was an inverted U to provide a skin flap for maturation of the appendiceal ACE stoma (fig. 1).

After all trocars were placed the appendix and cecum were mobilized as needed to reach the abdominal wall. The appendiceal tip was pulled out through the RLQ trocar to leave the umbilicus available for a catheterizable Mitrofanoff channel in the future, as needed. The trocar was removed and the appendiceal tip was excised. Several passes were made with an 8Fr or 10Fr catheter to ensure ease of catheter passage. The appendix was spatulated at its antimesenteric aspect and anastomosed to the inverted U skin flap in the RLQ. After it was sutured in place pneumoperitoneum could be maintained without CO_2 leakage.

Appendiceal imbrication or tunneling was not done in any case. Neither the cecum nor the appendix was secured to the anterior abdominal wall. The catheter remained in

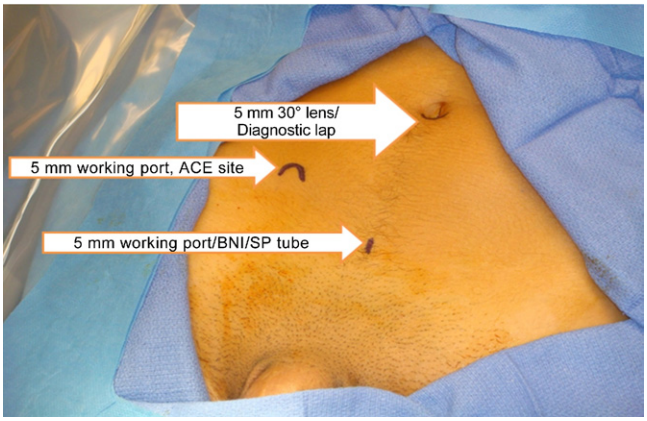

Figure 1. Three port sites in ambulatory 13-year-old boy with spina bifida.

place for 2 weeks while the appendiceal-cutaneous anastomosis healed. During that time patients were instructed to perform daily irrigations with 200 to 400 ml normal saline.

Antegrade bladder neck injection. The inferior midline trocar was removed and this port site was temporarily plugged to maintain pneumoperitoneum. The patient was placed in the Trendelenburg position help move the bowel cephalad. Cystoscopy was done via the urethra to inspect the bladder and determine the optimal puncture site on the mid anterior bladder. Under direct vision via the infraumbilical camera port a 14 gauge angiocatheter was introduced through the former inferior trocar site and into the transilluminated point on the bladder. Direct visualization and return of urine via the angiocatheter confirmed successful puncture. A 0.038-inch wire was fed through this angiocatheter into the bladder and the angiocatheter was removed using the Seldinger technique. An 11Fr peel away sheath was advanced over the wire into the bladder. Pneumoperitoneum was released, the infraumbilical trocar was removed and the incision was closed.

Antegrade cystoscopy was done through the sheath using a 9.5Fr offset pediatric cystoscope and the bladder neck was identified. Dx/HA was injected submucosally through a 23 gauge cystoscopic injection needle in all 4 quadrants. The Foley catheter or a feeding tube was intermittently advanced into and withdrawn from the urethra to help identify ideal injection points around the bladder neck and sense resistance to achieve optimal coaptation (fig. 2, *A*). Injection at the 12 o'clock position was often difficult due to the unnatural angle (fig. 2, *B*). In more recent cases we overcame this obstacle using the endoscopic Injekt™ needle. This side firing needle facilitates precise injection depth at difficult angles.

At the conclusion of the case an 8FR or 10Fr silicone catheter was placed through the peel away sheath to serve as a suprapubic tube. The balloon was inflated and the sheath was removed. The urethra was left without a urethral catheter. The patient was instructed not to perform intermittent catheterization for 2 weeks to prevent molding of the bulking implant.

RESULTS

Demographics and Surgical Indications

Between January 1, 2006 and August 1, 2008 a total of 10 combined LACE and ABNI procedures were done in 4 boys and 6 girls with a mean age of 9.4 years (range 6 to 13). All patients had spina bifida and myelomeningocele, and complained of severe constipation and stress urinary incontinence. In all cases each problem was refractory to pharmacological and other nonsurgical intervention. Seven patients were ambulatory with Canadian crutches and 3 were wheelchair bound (see table).

Regarding fecal impaction, all patients experienced significant constipation preoperatively despite having been instructed on a high fiber diets and proper hydration. Pharmacological intervention was used in all patients, such as polyethylene glycol or docusate. All patients received regular retrograde enemas, of whom many also required regular manual fecal disimpaction.

Regarding bladder function, all patients experienced stress urinary incontinence even when supine and stationary. All patients wore diapers and required multiple changes per day due to urinary and fecal soilage. All patients had a smooth walled bladder on preoperative cystogram. Mean preoperative bladder compliance was 27 ml/cm H_2O (range 20 to 37) and mean preoperative VLPP was 23 cm H_2O (range 10 to 40). Mean VLPP in ambulatory and nonambulatory patients was 23.4 and 21.3 cm H_2O, respectively (see table). In all patients bladder ca-

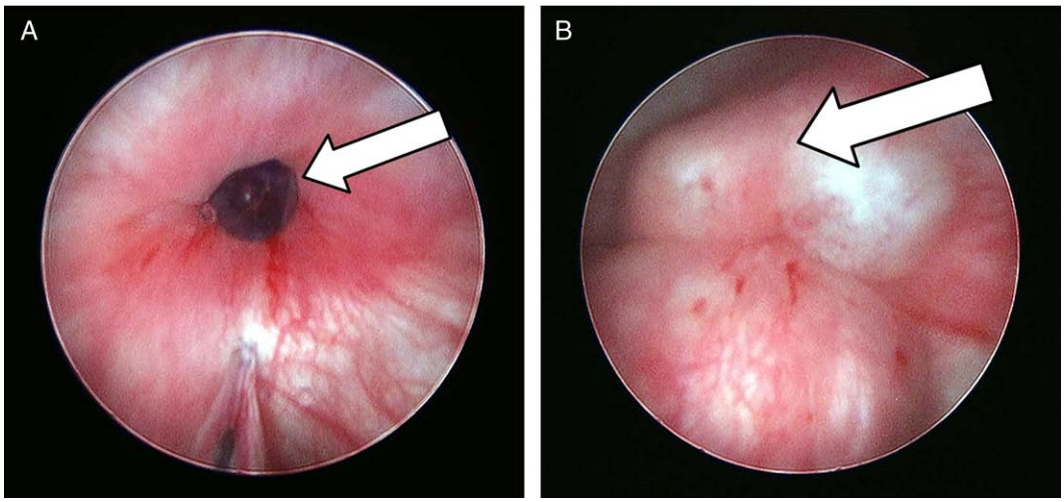

Figure 2. *A*, feeding tube (arrow) in bladder neck helps identify ideal injection site. *B*, ideal mucosal coaptation. Injection at 12 o'clock position (arrow) was achieved with significant difficulty.

Study cohort preoperative VLPP, postoperative continence and ambulatory status

Pt No.—	Age (yrs)—	Gender	Ambulatory	VLPP (cm H_2O) Preop	VLPP (cm H_2O) Postop, Failed ABNI	Diapers Preop	Diapers Postop	Postop ABNI Satisfaction*
1—	8	—M	Canadian crutches	40	46	Yes	Yes†	Yes
2—	9	—F	Not ambulatory	27		Yes	N	Yes
3—	6	—M	Canadian crutches	13		Yes	N	Yes
4—	13	—F	Not ambulatory	10		Yes	N	Yes
5—	9	—F	Canadian crutches	31		Yes	N	Yes
6—	9	—F	Canadian crutches	25		Yes	N	Yes
7—	9	—F	Canadian crutches	15	40	Yes	Yes	No
8—	7	—F	Canadian crutches	20	25	Yes	Yes	No
9—	13	—M	Not ambulatory	27		Yes	N	Yes
10—	10	—M	Canadian crutches	20		Yes	N	Yes
Mean (range)				22.8 (10–40)	37 (25–46)			

* All patients were satisfied with LACE.
† Diaper worn for confidence was soiled approximately once weekly.

pacity was at least 80% of that expected for age. All patients had been treated with anticholinergic therapy and all except 1 performed clean intermittent catheterization every 3 to 6 hours.

Operative Results

Mean operative time was 90 minutes (range 57 to 132). There were no intraoperative complications. Mean injected Dx/HA volume was 4.2 cc (range 3 to 6). All patients were discharged home within 24 hours of surgery.

Postoperative Results

Laparoscopic ACE. At a mean 18-month followup (range 12 to 27) all 10 patients were continent of stool and reported improved constipation with daily ACE irrigations of 200 to 400 ml saline. No patients required manual disimpaction postoperatively. No patient experienced stool or gas leakage via the ACE. All 10 patients were highly satisfied with the LACE outcome (see table).

Antegrade bladder neck injection. Seven of 10 patients (70%) were continent of urine and reported nonexistent diaper and pad use. Six of these 7 patients continued to perform intermittent catheterization every 4 hours. Patient 1, who reported improved urinary continence but at least weekly episodes of incontinence when ambulating, continued to wear diapers for confidence. Nonetheless, this patient and the 7 others who reported nonexistent diaper use (total 8 of 10 or 80%) reported improved quality of life since ABNI. The 2 patients who reported no change in postoperative diaper use compared to preoperative use reported unchanged quality of life in regard to urinary continence. However, these 2 patients were satisfied with ACE and reported that that part of surgery had improved quality of life (see table). All 10 patients underwent ultrasound postoperatively and none had any upper tract changes.

Preoperative VLPP in the 3 persistently diaper dependent patients was similar to that in the 7 who no longer wore diapers (25 and 22 cm H_2O, respectively). Two of the former patients were female and 1 was male. All 3 patients walked with Canadian crutches. Postoperatively UDS revealed various degrees of improvement in VLPP despite persistent wetness (see table).

No fully dry patient required repeat Dx/HA injection but patient 1 was scheduled for repeat injection. Patient 8 underwent repeat injection and reported marked improvement in diaper use.

DISCUSSION

First described in its current form in 1990 by Malone et al,[1] ACE entails creation of a channel through which enema fluid can be flushed in antegrade fashion. Various iterations have been reported since this initial description, including use of the appendix in orthotopic fashion. This technique, which was used in all cases in the current series, provides the significant advantage of preserving the native blood supply and theoretically mitigating the risk of stenosis. The obviation of tunnel creation also simplified the procedure and made it more amenable to a minimally invasive approach. Current patients undergoing the procedure can expect a greater than 90% continence rate and a 15% to 30% stenosis rate.[3–5]

The laparoscopic ACE procedure was initially described in dogs in 1996 by Cromie et al[6] and it was extended to humans soon after.[7,8] Currently approximately 14% of cases in the literature are done laparoscopically.[9] Comparably low leakage rates have been noted for open and laparoscopic techniques.[4] Many laparoscopic techniques involve a nonimbricated approach. Although investigators posit that combining the appendicocecal sphincteric mechanism and the length of the appendix used is suffi-

cient to prevent gas and fecal leakage, this point remains controversial.[4,5,10]

No patients in our series experienced stenosis and all were continent of stool. However, since our patient population was small and mostly prepubertal, we anticipate potential complications with changes in body habitus and social behavior. A recent study by Yardley et al showed that 18% of patients did not use MACE after 5 years and more than 40% did not use ACE at a mean 11-year followup.[11] Reasons for noncompliance varied. The fact that many patients were adolescents at followup likely contributed to some decrease in patient compliance. In patients who still regularly used ACE satisfaction remained high. Although our followup was somewhat short, long-term satisfaction and efficacy may mirror those in the mentioned series. Alternatively introducing a procedure with low morbidity at an early age may prove to enhance compliance in the long term.

In 1985 polytetrafluoroethylene was the first bulking agent described for ABNI[12] but this has since fallen out of favor due to particle migration and granuloma formation. Multiple other agents, including autologous fat, bovine collagen and polymethylsiloxane, have been investigated in the last 25 years. Although Dx/HA was originally developed for endoscopic treatment for vesicoureteral reflux, it has been the focus of most new investigations.

The results of injectable therapy for urinary incontinence are mixed. Some variation is readily explained by differences in technique, the material used as a bulking agent and heterogeneous patient populations. In a recent retrospective study Dyer et al compared Dx/HA to polytetrafluoroethylene and noted poor results in each group.[13] Only 1 of 20 and 1 of 14 patients injected with polytetrafluoroethylene and Dx/HA, respectively, were dry. All except 2 patients in that comprehensive report underwent injection in retrograde fashion. The remaining 2 patients were injected using a combined antegrade-retrograde approach. The marked difference between these results and ours is likely due largely to patient selection and the uniformly antegrade approach in our series.

Caione and Capozza noted a modest 43-minute improvement in the dry interval at 6 months but a decrement in improvement at 2-year followup.[14] Similarly Lottmann et al reported a significant decrease in success after 2 years to 40% at 7 years.[15] However, the decreasing number of patients in the cohort from years 1 (61) to 7 (5) may partly explain this observation since dry patients may not have sought followup.

The heterogeneity of the cohort in the study by Dyer et al may further explain the difference between their outcomes and ours.[13] In our series all patients had spina bifida with a good capacity, compliant bladder. The facts that all patients with exstrophy in that series did poorly and all 4 improved patients had age appropriate bladder capacity underscores the importance of patient selection and helps explain the higher efficacy of the procedure in our series. In fact, another 3 studies including only patients injected with Dx/HA showed cured or improved incontinence in 50% to 78%.[2,16,17] Our continence results compare favorably to those findings.

The antegrade approach to bladder neck injection may potentially maximize the overall continence rate. First described in 1996 by Abel and Gough,[18] several potential advantages increased the popularity of this technique and made it our first line approach. We believe that this approach allows more accurate needle placement at any bladder neck site and facilitates more accurate assessment of adequate mucosal coaptation. In our initial experience with ABNI we routinely determined immediate post-injection VLPP on manometry after all bulking agent was implanted. The antegrade approach facilitates a much more accurate manometric measurement since the urethra is unobstructed by a catheter, probe or cystoscope. However, we eventually abandoned this step since optimal coaptation almost invariably equated to a VLPP of greater than 60 cm H_2O and successful urinary continence.[2] However, we performed the Credé maneuver on the patient full bladder after optimal coaptation was achieved to confirm absent obvious leakage via the urethra.

Another advantage of the antegrade approach is the avoidance of post-procedural molding of the bulking agent, which could occur with immediate postoperative clean intermittent catheterization or urethral catheter drainage, by placement of a suprapubic catheter into the puncture site. Disadvantages of the antegrade approach include a small suprapubic incision and the attendant risk of bowel injury. However, these factors are significantly attenuated by laparoscopic visualization of the bladder puncture, as described. Moreover, the 5 mm suprapubic incision was already made for trocar placement for LACE in this single setting technique.

Although to our knowledge no statistically significant difference has yet been reported between the antegrade and retrograde techniques, 2 groups noted a trend toward improved continence for the antegrade technique.[2,17] In each study injections were done though antegrade as well as retrograde approaches and followup was 17 months or less in most patients. Although we exclusively used antegrade injection, it could be augmented by retrograde injection or more distal antegrade injection as needed.

To our knowledge no report exists of the long-term efficacy of ABNI using Dx/HA in a large pediatric cohort. However, 1 study exists in the adult

population.[9] Using antegrade collagen injection for post-prostatectomy stress incontinence a 10% cure rate was achieved with additional improvement in 35% of patients. Average followup was 28 months and all patients were treated with a single injection. However, the applicability of results in this cohort of men with post-prostatectomy incontinence who underwent collagen injection to children with myelomeningocele undergoing Dx/HA injection is limited.

A few potential limitations of this study deserve mention. Its retrospective nature subjects it to all of the potential problems inherent to any report with this study design. Also, precise definitions of success and cure are always elusive when studying therapy to treat a quality of life issue. Such difficulty is evident not only in evaluating our results but also in comparing them to those in other series. We think that our criteria, subjective though they are, may be better measures of success than a specific postoperative VLPP since the latter does not practically correlate with the degree of incontinence and in our experience the latter depends largely on patient mobility and activity status. Although our 3 patients in whom treatment failed were ambulatory, wheelchair bound patients typically have higher level spinal defects and may transfer frequently, making them as potentially vulnerable to stress incontinence as their ambulatory counterparts. However, the degree of bother of a small or occasional leak whether or not the patient wears diapers varies significantly among patients and families, particularly in the prepubertal age group. For this reason and despite imperfect correlation with clinical status postoperative VLPP data would have helped objectify our outcomes and its absence in our successful cases is a study limitation. Furthermore, the modest size of our cohort and our somewhat brief short-term followup may have inflated the success rate of the LACE and ABNI components of this procedure. While our main objective was to describe a novel approach to combine the 2 procedures, we hope that larger series will accrue.

CONCLUSIONS

Same setting LACE and ABNI is a safe, reasonably simple, minimally invasive approach to patients with spina bifida who have severe constipation and urinary incontinence. In carefully selected patients this combined procedure is highly efficacious. Single setting LACE and ABNI spares the morbidity of 2 separate procedures and does not compromise the safety or efficacy of each procedure done individually.

REFERENCES

1. Malone PS, Ransley PG and Kiely EM: Preliminary report: the antegrade continence enema. Lancet 1990; **336:** 1217.
2. Dean GE, Kirsch AJ, Packer MG et al: Antegrade and retrograde endoscopic dextranomer/hyaluronic acid bladder neck bulking for pediatric incontinence. J Urol 2007; **178:** 652.
3. Sinha CK, Grewal A and Ward HC: Antegrade continence enema (ACE): current practice. Pediatr Surg Int 2008; **24:** 685.
4. Karpman E, Das S and Kurzrock EA: Laparoscopic antegrade continence enema (Malone) procedure: description and illustration of technique. J Endourol 2002; **16:** 325.
5. Bani-Hani AH, Cain MP, Kaefer M et al: The Malone antegrade continence enema: single institution review. J Urol 2008; **180:** 1106.
6. Cromie WJ, Goldfischer ER and Kim JH: Laparoscopic creation of a continent cecal tube for antegrade colonic irrigation. Urology 1996; **47:** 905.
7. Webb HW, Barraza MA and Crump JM: Laparoscopic appendicostomy for management of fecal incontinence. J Pediatr Surg 1997; **32:** 457.
8. Hedican SP, Schylam PG and Docimo SG: Laparoscopic assisted reconstructive surgery. J Urol 1999; **161:** 267.
9. Sinha CK, Butler C and Haddad M: Left antegrade continence enema (LACE): review of the literature. Eur J Pediatr Surg 2008; **18:** 215.
10. Nanigian DK and Kurzrock EA: Intermediate-term outcome of the simplified laparoscopic antegrade continence enema procedure: less is better. J Urol 2008; **179:** 299.
11. Yardley IE, Pauniaho SL, Baillie CT et al: After the honeymoon comes divorce: long-term use of the antegrade continence enema procedure. J Pediatr Surg 2009; **44:** 1274.
12. Vorstman B, Lockhart J, Kaufman MR et al: Polytetrafluoroethylene injection for urinary incontinence in children. J Urol 1985; **133:** 248.
13. Dyer L, Franco I, Firlit CF et al: Endoscopic injection of bulking agents in children with incontinence: dextranomer/hyaluronic acid copolymer versus polytetrafluoroethylene. J Urol **178:** 1628.
14. Caione P and Capozza N: Endoscopic treatment of urinary incontinence in pediatric patients: 2-year experience with dextranomer/hyaluronic acid copolymer. J Urol 2002; **168:** 1868.
15. Lottmann HB, Margaryan M, Lortat-Jacob S et al: Long-term effects of dextranomer endoscopic injections for the treatment of urinary incontinence: an update of a prospective study of 61 patients. J Urol 2006; **176:** 1762.
16. Misseri R, Casale A, Cain M et al: Alternative uses of dextranomer/hyaluronic acid copolymer: the efficacy of bladder neck injection for urinary incontinence. J Urol 2005; **174:** 1691.
17. Kitchens DM, Minevich E, DeFoor WR et al: Incontinence following bladder neck reconstruction: is there a role for endoscopic management? J Urol 2007; **177:** 302.
18. Abel C and Gough DC: A novel approach to endoscopic injection at the bladder neck in childhood. Br J Urol 1996; **77:** 302.
19. Klutke J, Subir C, Andriole G et al: Long term results after antegrade collagen injection for stress urinary incontinence following radical retropubic prostatectomy. Urology 1999; **53:** 974.

EDITORIAL COMMENT

These authors describe an innovative operative approach combining LACE with ABNI to improve quality of life in children with neurogenic bowel and bladder incontinence. They conclude that this is safe, simple, minimally invasive and efficacious. Urinary continence was achieved in 70% of cases 18 months after injection. These results are encouraging and similar to those of other bladder neck surgery techniques. To provide an evidence-based outcome further studies are required that include objective preoperative and postoperative UDS assessment along with objective criteria for determining continence. However, is this therapy cost-effective? The hospital cost of Dx/HA now exceeds $1,800/1 ml. Based on this study the material cost alone would be $9,000 for 5 syringes with a reported average use of 4.2 ml per patient. Patient charges would be substantially higher. Who will be responsible for payment for any future procedure or study? As an off label technique, it is hard to justify that the cost of Dx/HA should become the obligation of insurance, Medicaid, the hospitals or the patient. On the other hand, is it reasonable to withhold treatment simply due to cost? It is our responsibility to answer these questions. If this innovative technique has real potential benefit in our patients, we must justify the expense and prove effectiveness in corporate sponsored trials.

David B. Joseph
Department of Pediatric Urology
University of Alabama at Birmingham
Children's Hospital
Birmingham, Alabama